


## Images For Diagnosis

# Extensive osteocartilaginous necrosis and naso-oral fistula

Jean-Baptiste Caruhel<sup>1,\*</sup> , and Anna Crambert<sup>2</sup>

<sup>1</sup> Oral and Maxillo-Facial Surgery Department, Sainte-Anne Military Hospital, Toulon

<sup>2</sup> Head and Neck Surgery Department, Percy Military Hospital, Paris

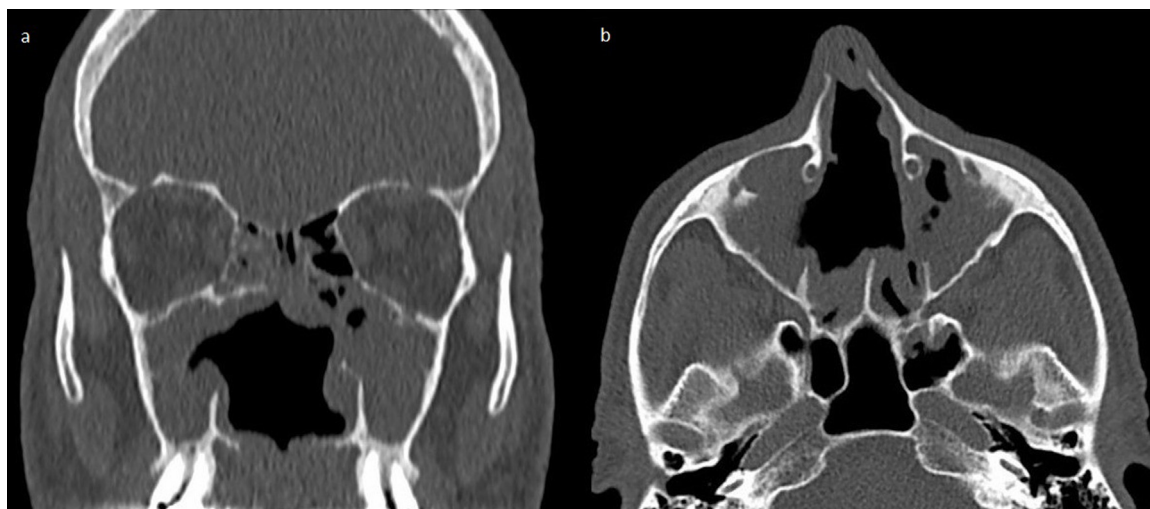
(Received: 5 July 2024, accepted: 30 October 2024)

A 54-year-old male patient presented to oral and maxillo-facial surgery department for management of a large naso-oral fistula. A computed tomography (CT) scan revealed extended necrosis of hard and soft palates, nasal septum and medial maxillary sinus walls (Fig. 1). The patient's file contained a CT scan that had been performed six years earlier; it showed intact intranasal structures and a deviated septum (Fig. 2).

Many different diagnoses could explain this local necrosis: autoimmune diseases (especially granulomatosis with poly-

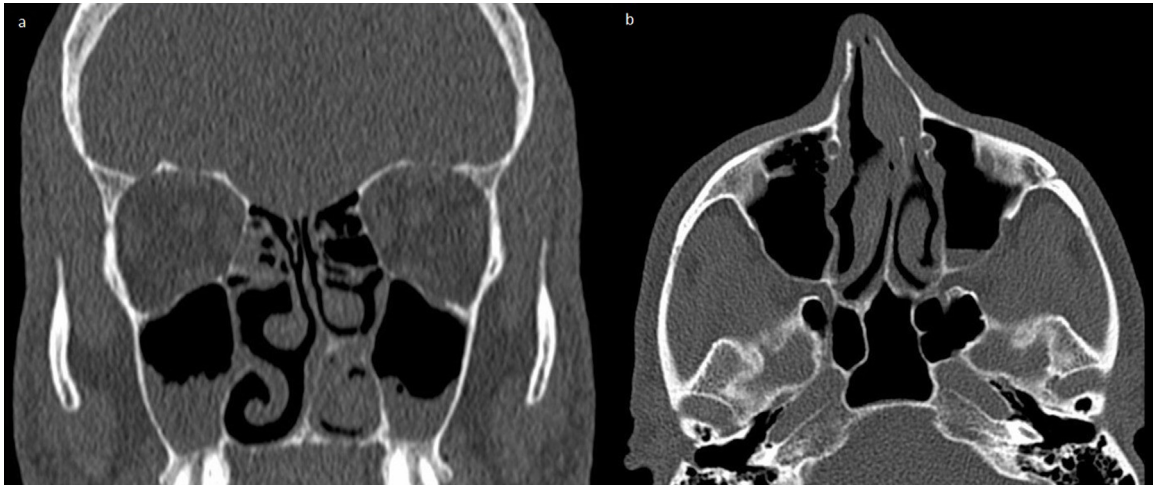
angiitis, *e.g.*, Wegener's granulomatosis), infections such as syphilis or leishmaniasis, iatrogenic causes and malignant lesions. The full investigation did not explain the large necrosis.

The patient ultimately revealed using cocaine by nasal insufflation for several months. Extended necrosis is not a common complication of cocaine abuse, as the most frequent alteration is a simple septal perforation. Cocaine-induced necrosis is another plausible diagnosis, but it should be selected only after eliminating other aetiologies.



**Fig. 1.** Coronal (a) and axial (b) planes of the current CT-scanner; large endonasal and palatal necrosis.

\* Correspondence: [docteur.caruhel@gmail.com](mailto:docteur.caruhel@gmail.com)



**Fig. 2.** Coronal (a) and axial (b) planes of the first CT-scanner, 6 years ago; highlighting intact oral and endo-nasal structures.

#### Funding

This research did not receive any specific funding.

#### Conflicts of interest

The authors declare that they have no conflict of interest.

#### Data availability statement

Data available on request from the authors. The data that support the findings of this study are available from the corresponding author upon reasonable request.

**Cite this article as:** Caruhel J-B, Crambert A. 2024. Extensive osteocartilaginous necrosis and naso-oral fistula. *J Oral Med Oral Surg.* 30, 30: <https://doi.org/10.1051/mbcb/2024030>