


## Images for Diagnosis

# A lobular capillary haemangioma on the lower lip

Sindhura Thanneru<sup>1</sup>, Suresh Mani<sup>2,\*</sup> 

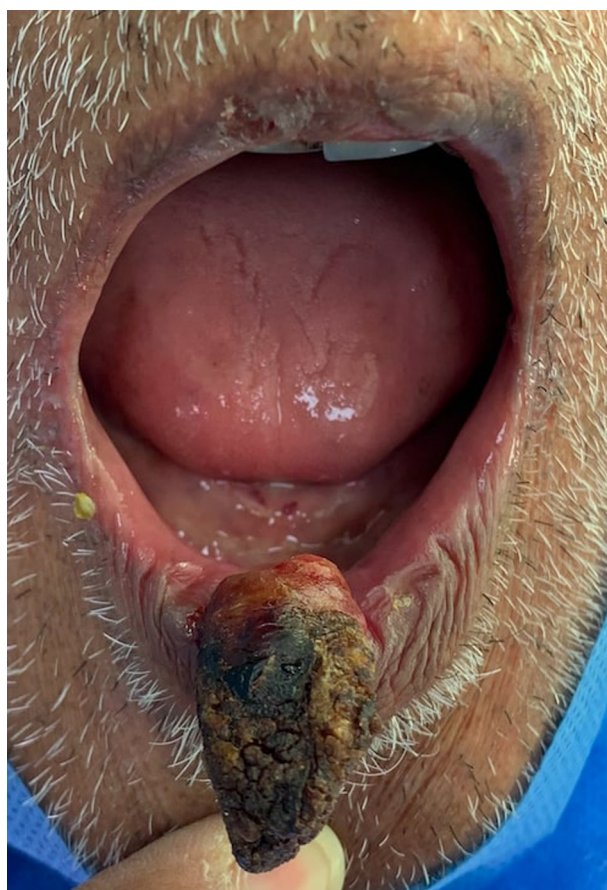<sup>1</sup> Department of Oto-Rhino-laryngology, AIIMS, New Delhi, India

<sup>2</sup> Department of Head and Neck Surgery, CMC, Vellore, India

(Received: 16 September 2022, accepted: 8 January 2023)

A 77-year-old man came to the ENT clinic with the complaint of painless and progressive swelling arising from the lower lip for a 4-years duration. No record of trauma to the lip or usage of dentures. He had come mainly concerned about the cosmetic problem caused by the lesion. There was no palpable cervical lymphadenopathy.

On examination, there was a single pinkish mass with a sessile base (Fig. 1), 0.5 × 0.5 cm in size, arising from the lower lip. It was hard in consistency and had a desiccated appearance. It was mildly tender with minimal bleeding at the base on palpation. Differential diagnoses were cutaneous horn, basal cell carcinoma, keratoacanthoma, and pyogenic



**Fig. 1** Pyogenic granuloma.

\* Correspondence: [msuresh.doc@gmail.com](mailto:msuresh.doc@gmail.com)

granuloma. A punch biopsy was taken from the lesion. The HPE findings were suggestive of pyogenic granuloma. Excision of the mass was performed under local anesthesia. The lip has healed after four weeks of follow-up.

### **Author contribution**

ST and SM have done the literature search, manuscript preparation, and designing, and SM has edited the final manuscript. A separate contribution form is attached.

### **Conflict of interest**

The authors declare that they have no conflict of interest in relation to this article.

### **Source of funding**

This research did not receive any specific funding.

### **Informed consent**

Informed consent was taken from the patient to publish.

### **Ethical approval**

Ethical approval was not required.