

## Original Article

# Does magnitude of deformity correlate with functional outcome following closed reduction in unilateral condylar fracture?

Syed Nabil\*, Abdul Jabar Nazimi

Department of Oral and Maxillofacial Surgery, Faculty of Dentistry, Universiti Kebangsaan Malaysia, Kuala Lumpur, Malaysia

(Received: 13 July 2020, accepted: 30 November 2020)

**Keywords:**  
Mandible / condyle / fractures / intermaxillary fixation / cone beam computed tomography

**Abstract – Introduction:** Condyle fracture can be treated surgically (ORIF) or conservatively (CTR). When treated by CTR, the fracture might not heal in a morphologically ideal shape. The severity of the deformity and its effects on the functional outcome is not known. This study would investigate the anatomical outcome of CTR and its effect on the functional outcome. **Methods:** Using a cross-sectional study design, we enrolled patients identified from our trauma census that meets the pre-determined inclusion criteria. Patient underwent assessment which involves clinical and radiographic evaluation. Clinical examination was done by using Helkimo Index. Radiographic evaluation by using cone beam computed tomography (CBCT) scan were traced and digitized, and the position and morphology of the fractured mandibular condyle was measured and compared with those of the contralateral non-fractured condyle in the axial, coronal and sagittal planes. Radiographic data was then compared with data from clinical examination. **Results:** 25 patients with unilateral condyle fracture and met the inclusion criteria were identified. Eight patients were successfully recalled and included in the study. Assessment was done on average of 40 months post-treatment. Clinical assessment with Helkimo Index showed that 63% had at least mild temporomandibular symptoms or dysfunction. CBCT examinations revealed that most patients had morphologically deformed healed condyle. No pattern can be seen in the magnitude of deformity with functional outcome. **Conclusions:** Following CTR, condyle fracture would heal in a morphologically deformed shape. Satisfactory functional outcome is still attainable despite this. The magnitude of the deformity does not appear to influence the functional outcome.

## Introduction

The mandible is the most commonly involved bone fractures in maxillofacial trauma [1]. Further analysis of these mandibular fractures shows that condyles are the most frequent fracture site involved [1]. In managing condyle fractures, the discussion regarding conservative therapy (CTR) or Open reduction with internal fixation (ORIF) is still on-going [2]. There are several factors when deciding on either therapy which includes uni or bilateral fractures, age of patient, level of fracture, degree/direction of displacement, medical status of patient, concomitant injuries, presence/status of dentition, occlusion and presence of foreign body [3,4]. There is however a noticeable trend of increasing acceptance for ORIF to be the treatment of choice for most condylar fractures [2]. This recent change is backed by evidence that suggest ORIF has better outcome in specific parameters including occlusion, protrusion, laterotrusion and lateral deviation compared with non-surgical approach [5].

CTR however is still relevant today mainly because it provides an acceptable functional outcome minus all the risk of surgery [6,7]. From the surgeon point of view, it is technically much easier compared to ORIF where the limited space makes it difficult to manipulate fracture fragments [7]. Another important factor is the financial aspect of it, with some patient unable to consider ORIF due to its higher cost. A recent study has been estimated that the average cost of ORIF is USD51,145 for unilateral condylar fracture which was significantly higher compared to CTR cost of USD32,091 [8]. The main drawback of CTR is that a good anatomic repositioning may not be achieved, contributing to poorer long-term outcome compared to surgical approach [6,7]. Earlier analysis of anatomical outcome by Konstantinovi and Dimitrijevi confirmed that ORIF provides better re-positioning of the fractured condyle [9]. More recently, Danda *et al.* found a better anatomic reduction in patients undergoing ORIF treatment [6]. Both studies however found acceptable functional outcome regardless of the less than ideal anatomical reduction seen in CTR group [6,9].

While previous studies has shown the condyle would be more deformed following CTR compared to ORIF, the

\* Correspondence: [syednabil@ppukm.ukm.edu.my](mailto:syednabil@ppukm.ukm.edu.my)

significance of the magnitude of deformity on the functional outcome has never been explored. As the inability to achieve anatomical repositioning seems to be the main disadvantage in CTR approach, it would be of interest to further explore its significance. The aim of this study is therefore to evaluate the anatomical outcome of CTR for unilateral mandibular condyle fractures. We also would further assess the functional outcome in relation to the deformity magnitude.

**Materials and methods**

This study was approved by the Universiti Kebangsaan Malaysia Medical Centre (UKMMC) ethical board. The trauma census of patients treated in the UKMMC over 10 years period were reviewed. Patients with condylar fracture were identified and their hospital records were obtained. The demographic, clinical data and orthopantomograms (OPG) radiographs were reviewed. Cases meeting the inclusion criteria listed in [Table I](#)

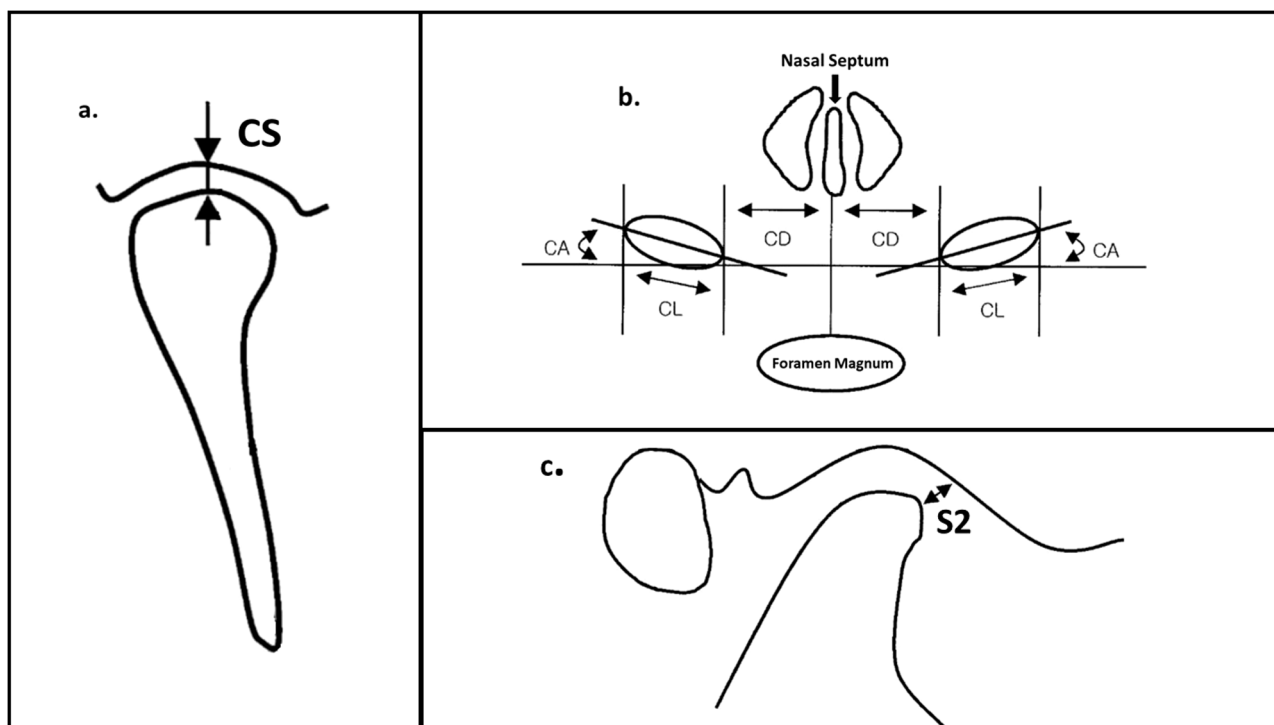
**Table I.** Inclusion criteria for subject to be included in study.

Criteria to be included in study
Had unilateral condylar fracture
Condylar fracture treated with conservative management
Available Orthopantomogram radiograph done within 24 hours following trauma
Completed treatment for at least 1 year

were included in the study. All eligible patients were then recalled for cross-sectional clinical and radiographic assessment.

Informed consent was obtained from all patients who responded to the recall. They underwent clinical assessment using The Helkimo index scoring system. The Helkimo anamnestic index (Ai) score was obtained through a standardize questions asked by a single clinician (SN). For the Helkimo dysfunction Index (Di) score, clinical examination was done by the same clinician. They were also ask to rate their perceived functional outcome following treatment using a 5-point likert scale. Subjects were asked "How do you rate your current chewing function?" and was given option to rate ranging from "very poor", "poor", "acceptable", "good" and "very good". Finally, during the same visit, a radiographic assessment was performed through Cone Beam Computed Tomographic (CBCT) scan. An i-CAT CBCT machine was used with the following scan parameters: scan time 8.9 s; 120 kV; and 10.54 mAs.

For the radiographic analysis, firstly the condyle fractures sustained was classified based on the immediate post-trauma OPG. The fractures was categories into classification as described by Loukota *et al.* [10]. Then the axial, coronal and sagittal CBCT images featuring both condyles were traced and digitized based on a landmark and parameters previous described by Choi *et al.* [11] (see [Fig. 1](#)). Specific parameters were used for the purpose of this study ([Tab. II](#)). Both condyles, the healed fractured condylar process and the contralateral non-fractured condylar process was measured. Because there is



**Fig. 1.** Schematic drawing of the CT measurements made in coronal (a), transverse (b) and sagittal (c) view. Image original source from Choi *et al.* [11].

**Table II.** Parameters used in radiological assessment based on the study by Choi *et al.* [11].

Parameters	Landmark	Purpose
<b>Axial</b>		
Paramedian line (PL)	vertical line passing through the nasal septum and the centre of the occipital foramen	As reference line
Transverse line (TL)	line tangentially to the posterior borders of both condyles	As reference line
Condylar Distance (CD)	distance between the condyle and the paramedian line	To measure magnitude of medial or lateral displacement
Condylar Length (CL)	the longest diameter of the condyle	To measure magnitude of deformity of condylar head
Condylar Angulation (CA)	the angulation between the long axis of the condyle and the transverse line	To measure magnitude of rotation of condylar head
<b>Coronal</b>		
Coronal Joint Space (CS)	Superior joint space (in coronal view)	To measure magnitude of superior or inferior displacement
<b>Sagittal</b>		
Anterior joint space (S2)	Closest anterior joint space	To measure magnitude of anterior or posterior displacement

no imaging of the fractured condyle before injury, for the purpose of this study, it is assumed that the contralateral non-fractured condyle mirrors in shape and location to the fractured condyle original anatomical form. The differences in the radiological measurement between fractured and non-fractured condyle were documented and were used as a measure of the deformity of the fractured condyle following healing. The measurement in the condylar distance (CD), coronal joint space (CS) and anterior joint space (S2) representing the changes in medio-lateral, superio-inferior and antero-posterior direction. These three parameters measurement was then summed up to give the calculated total displacement magnitude. This reading was then categorised into mild (2.0–4.9 mm), moderate (5.0–9.9 mm) and severe (10.0 mm and above) displacement. The condylar length (CL) reading was also categorised into mild, moderate and severe deformity for reading 0.5–0.9 mm, 1.0–1.9 mm and more than 2.0 mm respectively. Finally, the condyle rotation was similarly categories to mild (2.0°–4.9°), moderate (5.0°–9.9°) and severe (10.0° and above). Measurement below the minimum value are considered to have no significant difference compared to the non-fractured side. Data collection was recorded in a proforma form that was later transferred to Microsoft Excel® for tabulation.

## Results

A total 183 cases of mandibular fractures over 10 years period was identified. Among those, 25 patients had unilateral condylar fracture and met the inclusion criteria. Eight patients were successfully recalled and included in the study. The included patients were all male with age ranging from 19 to

58 years old. All but one of them sustained the condyle fracture due to motor vehicle accident. The other remaining sustained the fracture following a fall. Patient's clinical and radiographic assessment was performed at the average of 40 months after treatment. Majority (6 out of 8) of the patient in this study had sustained condylar neck fracture. The remaining two had each sustained condylar base and diacapitular types of fracture. Half of the patients had also sustained mandibular fractures, all of which was treated with open reduction and internal fixation. The intermaxillary fixation (IMF) treatment protocol was similar for all patients who sustained condylar neck and condylar base fracture consisting 2 weeks of wire fixation before switching to guiding elastics for another 4 weeks. One patient that had diacapitular fracture underwent 6 weeks guiding elastic instead. The demographic and clinical data of the included patients are detailed in [Table III](#).

According to Helkimo Anamnestic index (Ai) assessment, it was noted that three patients had no symptoms; one had mild symptoms while rest of the patients had severe symptoms ([Tab. IV](#)). Three out of four of patients with severe symptoms had both pain in the masticatory muscles/joints and pain during movement. There were also two patients of the severe symptom category that had limitation in mouth opening. On Helkimo Dysfunction Index (Di) assessment, two had moderate dysfunction and three had mild dysfunction. Both of the patients who had moderate dysfunction on Di had severe symptoms on Ai. When asked about their current chewing function, six of them had at least good or very good function ([Tab. V](#)). The remaining two had acceptable or poor perceived chewing function. In both of these patients, their Di score was in the moderate dysfunction category. None rated their chewing ability as very poor.

**Table III.** Patients' demographics and clinical information.

Patient no.	Gender	Age (years)	Race	Etiology	Period (months)	Condyle side	Classification (Loukota <i>et al.</i> )	Other maxillofacial bony injuries	Treatment	MMF Protocol
1	Male	19	Malay	MVA	28	Left Condyle	Condylar neck	Symphysis of mandible fracture	ORIF symphysis fracture and IMF condyle fracture	2 week IMF with wire + 4 week with elastics
2	Male	26	Malay	MVA	22	Left Condyle	Condylar neck	Right body of Mandible fracture	ORIF body fracture and IMF condyle fracture	2 week IMF with wire + 4 week with elastics
3	Male	21	Malay	MVA	30	Left Condyle	Diacapitular	nil	IMF condyle fracture	6 week IMF with elastics
4	Male	58	Indian	MVA	51	Right Condyle	Condylar neck	Right Zygomatic Complex Fracture	Conservative zygomatic fracture and IMF condyle fracture	2 week IMF with wire + 4 week with elastics
5	Male	39	Malay	MVA	132	Left Condyle	Condylar neck	Right parasymphysis of mandible fracture	ORIF parasymphysis fracture and IMF condyle fracture	2 week IMF with wire + 4 week with elastics
6	Male	50	Malay	Fall	22	Left Condyle	Condylar neck	Right parasymphysis of mandible fracture	ORIF parasymphysis fracture and IMF condyle fracture	2 week IMF with wire + 4 week with elastics
7	Male	24	Malay	MVA	12	Right Condyle	Condylar neck	nil	IMF condyle fracture	2 week IMF with wire + 4 week with elastics
8	Male	21	Malay	MVA	20	Right Condyle	Condylar base	nil	IMF condyle fracture	2 week IMF with wire + 4 week with elastics
<b>Mean</b>		<b>32.3</b>			<b>39.6</b>	<b>Mean</b>				

MVA, motor vehicle accidents; ORIF, open reduction and internal fixation; IMF, inter-maxillary fixation.

When assessed radiographically, three of the patients are considered to have severe displacement based on the differences in the healed fractured condyle position compared to the non-fractured condyle position (Tab. V). Six of eight patients had medial displacement (CD measurement shorter in the fractured side). Seven of them were noted to be positioned more superiorly compared to the non-fractured side. Antero-posteriorly, three condyles had healed at a more anterior location compared to the non-fractured side. Overall, three fractured condyle was considered to be severely displaced compared to the non-fractured side. When the maximum length of the condyle head (CL distance) was compared between fractured and non-fractured sides, unsurprisingly, only one which was the diacapitular fracture that was severely deformed. When condyle angles (CA angulation) were compared for fractured condyle rotational assessment, it was noted that majority cases had moderate rotation. Two had severe rotation of more than 10°.

There was no pattern in regard of Helkimo Index results (Tab. IV) with radiographic parameters (Tab. V). Among the three cases (patient no 4, 5 and 6) with no symptoms (Ai 0) and no dysfunction (Di 0), all had moderate to severe radiographic parameters in the displacement magnitude, condyle head deformity and condylar head rotation. Conversely, in the four patients (patient no 1, 2, 3 and 8) with severe Ai symptoms, 3 had only mild displacement magnitude. One of them also had no significant condylar head deformity and no condylar head rotation.

### Discussion

One of the primary goal of treatment of any traumatic injury is to restore function to pre-trauma state. In condyle fracture, this aim is essentially re-establishing the normal functional occlusion. It has been ascertained from previous studies that both available therapeutic approaches namely CTR and ORIF are able to achieve this aim [6,7,9]. ORIF treatment provides the ability to reduce the fractures to its ideal anatomical form which would allow more predictable functional outcome [11]. CTR is still relevant because in specific clinical situation, it may obtain equivalent functional outcome when compared to ORIF. Because CTR is cheaper, simpler and safer, it should be the treatment of choice when equal functional outcome can be obtained [3]. For example, CTR is traditionally the treatment of choice for paediatric condyle fractures and diacapitular fracture [12,13]. While recent trends suggest more acceptance for ORIF, controversies still exist with factors such as severity of dislocation/displacement, presence of dysocclusion and level of fracture are scrutinized [2,14]. Recent consensus suggests that, ORIF should be the treatment of choice for lower level condylar fracture, [2,14]. This is also the practice in our centre, explaining on the reason for having only one case of condylar base fracture in this series.

The most obvious benefits of CTR are the absence of surgical complications such as facial nerve damage, infection,

**Table IV.** Clinical assessment with Helkimo Index.

Anamnestic index (Ai)/Dysfunction Index (Di) Score	Patient 1	Patient 2	Patient 3	Patient 4	Patient 5	Patient 6	Patient 7	Patient 8
Do you hear a sound in TMJ area (clicking/crepitations)	Y	Y	Y	N	N	N	Y	Y
Do you have jaw rigidity/stiffness on awakening or slow movement of the mandible	N	N	N	N	N	N	N	N
Do you feel fatigue in the jaw area	Y	N	N	N	N	N	N	Y
Do you have difficulty when opening the mouth/limitation in mouth opening	N	Y	Y	N	N	N	N	N
Do you have locked mandible during opening of mouth	N	N	N	N	N	N	N	N
Do you have pain in the TMJ or in the area of masticatory muscle	Y	N	Y	N	N	N	N	Y
Do you have pain during movement of the mandible	N	N	N	N	N	N	N	N
Do you have luxation of the mandible	N	N	N	N	N	N	N	N
<b>Ai INDEX (0/1/2)</b>	<b>2</b>	<b>2</b>	<b>2</b>	<b>0</b>	<b>0</b>	<b>0</b>	<b>1</b>	<b>2</b>
Impaired range of movement/mobility index	<b>Severe Symptoms</b>	<b>Severe Symptoms</b>	<b>Severe Symptoms</b>	<b>No Symptoms</b>	<b>No Symptoms</b>	<b>No Symptoms</b>	<b>Mild Symptoms</b>	<b>Severe Symptoms</b>
Impaired TMJ function	1	0	1	0	0	0	0	1
Muscle pain	0	0	1	0	0	0	0	5
TMJ pain	0	0	1	0	0	0	0	1
Pain on movement of the mandible	0	0	1	0	0	0	0	1
<b>Total Score</b>	<b>2</b>	<b>1</b>	<b>5</b>	<b>0</b>	<b>0</b>	<b>0</b>	<b>1</b>	<b>8</b>
<b>Di INDEX (0/1/2/3)</b>	<b>1</b>	<b>1</b>	<b>2</b>	<b>0</b>	<b>0</b>	<b>0</b>	<b>2</b>	<b>2</b>
	<b>Mild dysfunction</b>	<b>Mild dysfunction</b>	<b>Moderate dysfunction</b>	<b>No dysfunction</b>	<b>No dysfunction</b>	<b>No dysfunction</b>	<b>Mild dysfunction</b>	<b>Moderate dysfunction</b>

**Table V.** Radiological assessment with Cone beam CT.

Parameters	Patient 1	Patient 2	Patient 3	Patient 4	Patient 5	Patient 6	Patient 7	Patient 8
<b>Helkimo Index</b>								
Anamnestic index (Ai)								
Dysfunction Index (Di)								
Perceived Chewing Function								
<b>Displacement magnitude parameters</b>								
Medio-lateral plane								
Superio-inferior plane								
Antero-posterior plane								
Sum of displacement								
Mild: 2.0–4.9 mm, Moderate: 5.0–9.9 mm, Severe: 10.0 mm and above								
<b>Deformity changes parameters</b>								
Condyle head deformity								
Mild: 0.5–0.9 mm, Moderate: 1.0–1.9 mm, Severe: 2.0 mm and above								
<b>Rotation changes parameters</b>								
Condyle head rotation								
Mild: 2.0°–4.9°, Moderate: 5.0°–9.9°, Severe: 10.0° and above								

\*Negative or positive value indicate direction of displacement.

#When calculating magnitude of displacement, direction are not considered.



scarring, sialoceles and implant-related issues [7,9,15]. On longer follow-up, previous reports suggest that CTR has higher rate of pain, asymmetry, restricted mandibular movement, deviation on movement, malocclusion and pathological changes in the temporomandibular joint (TMJ) [7,15,16]. In this study, we selected cases with at least 1 year post-treatment period, to allow complete healing and resolving any early acute issues. Our results show that TMJ disorder are quite common following non-surgical treatment, with only 37% of our subjects had no symptoms (Ai 0) or dysfunction (Di 0) in both Helkimo Ai and Di assessment. This is slightly better when compared to the finding by Kokemueller *et al.* who noted that in their CRT group, at 1 year, 29% had no symptoms on Ai and only 10% had no dysfunction on Di [7]. Contrasting this, earlier study by Hlawitschka *et al.* found only 3% of their subjects who underwent CTR had no dysfunction on Di [16]. More recently, Ren *et al.* found in their assessment, only 19% had no symptoms on Ai and 0% had no dysfunction on Di following CTR [17]. Interestingly, both the study by Hlawitschka *et al.* and Ren *et al.* were exclusively diacapitular condylar fracture patients, and had worst functional outcome than this and Kokemueller *et al.* study which had majority of condylar neck fracture [7,16,17]. It was also evident that the only patient sustaining diacapitular fracture in our sample had one of the worst functional outcome in our series. Despite most patient in the present study had some form of TMJ disorder, they appear to be able to tolerate it well, with some of them perceived their chewing ability as good even with significant symptoms or dysfunction. This is likely because clinicians have a more objective eye for complications even though patient were never troubled with it [18]. It should be noted that it is possible that symptoms would worsen over time following CTR, thus long-term follow-up is needed [7,19].

The development of TMJ disorder is possibly due to the stress induced on the contralateral non-fractured condyle due to non-ideal form of the fractured condyle following trauma [20]. Our analysis confirms that, the condyle, irrespective of level of fractures, would heal in a deformed or displaced position post CTR. However, no cases of non-union were seen. This confirms the previous two-dimensional imaging analysis of CTR treated condyle fractures heals in a deformed state [6,9,19]. A three dimensional imaging study of condyle fracture treated with closed reduction also concurred with our finding that displaced fractured condyle would heal in a deformed shape [21]. This is opposed to surgically treated condyles, where three dimension analyses found no morphological differences when compared to the contralateral non-fractured condyle [11]. In regards of the magnitude of deformity in relation to the fracture level, our analyses shows that the most severely displaced are in the subcondylar fracture while the least displaced is the diacapitular fracture. This finding however is possibly incidental, as the lack of representative from diacapitular and subcondylar fracture in this sample plus the overall small sample size makes it impossible to draw firm conclusion.

The findings of this study suggest that, good functional outcome is possible to be attained with closed reduction. In our series of patients, cases with the most severe displacement and condylar head deformity had the most affected functional outcome. Accidentally, these two cases are the only cases which are not condylar neck fracture. But looking in more detail, few other cases with severe displacement magnitude had actually no to mild symptoms or dysfunction. Thus, no clear pattern can be seen in regards of symptoms (Ai index) and clinical signs (Di index) severity with the worsening radiological parameters. Our finding is therefore in agreement with previous statement that no relationship between the magnitude of displacement with the attainment of satisfactory functioning [22]. Similarly, we found that the radiological parameters have not significant bearing on the patient's perceived chewing function. Additionally, because the lack of relationship in radiological parameters with functional outcome, it is not always possible to predict satisfactory results following CTR. ORIF main advantage is therefore its ability to provide more consistent and predictable outcome following anatomical reduction to pre-trauma state. For example, De Riu *et al.* found that greater homogeneity in occlusal parameters in ORIF when compared to CTR [19]. Furthermore, with a deformed unilateral condyle, the ramification of persistently overloading the non-fractured condyle is not clear [20]. While there is suggestion of condylar morphological adaptation even in adults, longer period of follow-up data are needed to ascertain CTR functional outcome over the long-term [23].

It is also important to explain the lack of consistency in CTR treatment outcome. It is known that with CTR treatment, there are multiple other confounding factors that can affect the outcome. These factors include the type and length of IMF treatment, attitude towards treatment (such as compliance to physiotherapy), pre-injury occlusion/TMJ dysfunction, and its associated or concomitant fractures. In our centre, the protocol for extracapsular condylar fracture is 2 weeks of rigid IMF with ligature wire followed by 4 weeks of guiding elastic bands. For intracapsular fractures, a 6 weeks guiding elastics is used instead. It is not possible to compare between these two protocols as it is used for different condylar fractures. However for extracapsular fractures, as all cases received similar IMF protocol, this effectively excluding it as a confounder for this study. Our protocol of total 2 weeks of rigid IMF appear in line with suggestion from previous research who noted 4 weeks of immobilization significantly reduce mouth opening [24]. Despite that, half of the patient in the current study had impaired range of movement on clinical examination. All patients were given instruction on jaw opening exercise after treatment, but adherent to these instructions was not assessed. Furthermore, the effectiveness of this jaw exercise is also not known. We also did not explore the presence of pre-trauma TMJ disorder formally. Thus, we did not rule out the possibility that the symptoms or signs seen after treatment are due to pre-existing condition. In regards of the associated fractures, cases without other maxillofacial fractures do not appear to have better outcomes. In fact, the 3 cases that had no symptoms and

no dysfunction on Helkimo index had associated jaw fractures. This is in contrast to previous finding of more severe TMJ disorder when there are contralateral fracture of angle or body of mandible [20].

Despite the small sample size, it is clear that no pattern can be seen in regards of the magnitude of deformity with the functional outcome following CTR. Another limitation is the lack of comparable group of patient that underwent ORIF. Thus, the assumption that a better functional outcome would have been obtained if this sets of patients underwent ORIF instead of CTR cannot be made from the results of this study alone.

## Conclusion

In conclusion, three-dimensional radiological result conclusively found that the fractured condyles are not likely to be anatomically restored to its ideal form following CTR. While it is possible to attained good clinical results from such therapeutic approach, it is not possible to predict the functional outcome based on radiological parameters. Further investigation is needed to explore other factors that could influence the treatment outcome following CTR.

## Funding

This study was funded by the National University of Malaysia internal grant code: GGPM-2011-077.

## Competing interests

None.

## Ethical approval

Ethical approval was obtained from the institution ethical committee. The Universiti Kebangsaan Malaysia ethics reference number are UKM 1.5.3.5/244/FGG-003-2013.

## Patient consent

Written consent was obtained from all subjects participating in this study.

**Acknowledgments.** The authors would like to thank Dr Lai Hui Yin, Dr Ng Shay Lee, Dr Nurafida Idris and Dr Nurainina Rahimi Abd Rahim for the assistance in reviewing the trauma census list.

## References

- Ramli R, Rahman NA, Rahman RA, Hussaini HM, Hamid AL. A retrospective study of oral and maxillofacial injuries in Seremban Hospital, Malaysia. *Dent Traumatol* 2011;27:122–126.
- Neff A, Chossegros C, Blanc JL, Champsaur P, Cheynet F, Devauchelle B, *et al.* Position paper from the IBRA Symposium on Surgery of the Head—the 2nd International Symposium for Condylar Fracture Osteosynthesis, Marseille, France 2012. *J Craniomaxillofac Surg* 2014;42:1234–1249.
- Hayward JR, Scott RF. Fractures of the mandibular condyle. *J Oral Maxillofac Surg* 1993;51:57–61.
- Villarreal PM, Monje F, Junquera LM, Mateo J, Morillo AJ, Gonzalez C. Mandibular condyle fractures: determinants of treatment and outcome. *J Oral Maxillofac Surg* 2004;62:155–163.
- Chrcanovic BR. Surgical versus non-surgical treatment of mandibular condylar fractures: a meta-analysis. *Int J Oral Maxillofac Surg* 2015;44:158–179.
- Danda AK, Muthusekhar MR, Narayanan V, Baig MF, Siddareddi A. Open versus closed treatment of unilateral subcondylar and condylar neck fractures: a prospective, randomized clinical study. *J Oral Maxillofac Surg* 2010;68:1238–1241.
- Kokemueller H, Konstantinovic VS, Barth EL, Goldhahn S, von See C, Tavassol F, *et al.* Endoscope-assisted transoral reduction and internal fixation versus closed treatment of mandibular condylar process fractures—a prospective double-center study. *J Oral Maxillofac Surg* 2012;70:384–395.
- Kuang SJ, He YQ, Zheng YH, Zhang ZG. Open reduction and internal fixation of mandibular condylar fractures A national inpatient sample analysis, 2005–2014. *Medicine* 2019;98.
- Konstantinovic VS, Dimitrijevic B. Surgical versus conservative treatment of unilateral condylar process fractures: clinical and radiographic evaluation of 80 patients. *J Oral Maxillofac Surg* 1992;50:349–352; discussion 352–353.
- Loukota RA, Eckelt U, De Bont L, Rasse M. Subclassification of fractures of the condylar process of the mandible. *Br J Oral Maxillofac Surg* 2005;43:72–73.
- Choi BH, Huh JY, Yoo JH. Computed tomographic findings of the fractured mandibular condyle after open reduction. *Int J Oral Maxillofac Surg* 2003;32:469–473.
- McGoldrick DM, Parmar P, Williams R, Monaghan A, McMillan K. Management of pediatric condyle fractures. *J Craniofac Surg* 2019;30:2045–2047.
- Landes CA, Day K, Lipphardt R, Sader R. Closed versus open operative treatment of nondisplaced diacapitular (Class VI) fractures. *J Oral Maxillofac Surg* 2008;66:1586–1594.
- Kommers SC, Boffano P, Forouzanfar T. Consensus or controversy? The classification and treatment decision-making by 491 maxillofacial surgeons from around the world in three cases of a unilateral mandibular condyle fracture. *J Craniomaxillofac Surg* 2015;43:1952–1960.
- Garcia-Guerrero I, Ramirez JM, Gomez de Diego R, Martinez-Gonzalez JM, Poblador MS, Lancho JL. Complications in the treatment of mandibular condylar fractures: surgical versus conservative treatment. *Ann Anat* 2018;216:60–68.
- Hlawitschka M, Loukota R, Eckelt U. Functional and radiological results of open and closed treatment of intracapsular (diacapitular) condylar fractures of the mandible. *Int J Oral Maxillofac Surg* 2005;34:597–604.
- Ren R, Dai J, Zhi Y, Xie F, Shi J. Comparison of temporomandibular joint function and morphology after surgical and non-surgical treatment in adult condylar head fractures. *J Craniomaxillofac Surg* 2020;48:323–330.
- Ellis E, 3rd. Complications of mandibular condyle fractures. *Int J Oral Maxillofac Surg* 1998;27:255–257.
- De Riu G, Gamba U, Anghinoni M, Sesenna E. A comparison of open and closed treatment of condylar fractures: a change in philosophy. *Int J Oral Maxillofac Surg* 2001;30:384–389.



20. Tabrizi R, Bahramnejad E, Mohaghegh M, Alipour S. Is the frequency of temporomandibular dysfunction different in various mandibular fractures? *J Oral Maxillofac Surg* 2014; 72:755–761.
21. Yamashita Y, Inoue M, Aijima R, Danjo A, Goto M. Three-dimensional evaluation of healing joint morphology after closed treatment of condylar fractures. *Int J Oral Maxillofac Surg* 2016;45:292–296.
22. Bos RR, Ward Booth RP, de Bont LG. Mandibular condyle fractures: a consensus. *Br J Oral Maxillofac Surg* 1999;37:87–89.
23. Lindahl L, Hollender L. Condylar fractures of the mandible. II. A radiographic study of remodeling processes in the temporomandibular joint. *Int J Oral Surg* 1977;6:153–165.
24. de Amaratunga NA. Mouth opening after release of maxillomandibular fixation in fracture patients. *J Oral Maxillofac Surg* 1987;45:383–385.