

Technical Note

Transplant surgical templates for dental autotransplantation: a technical note

Louise Tavenne¹, Pierre-Alexandre Chataigner², Olivier Sorel³, Victor Fau^{4,*}

¹ Dental and Oral Medicine Resident, CHU Rennes, Rennes, France

² Orthodontics Resident, CHU Rennes, Rennes, France

³ PU-PH Orthodontics, CHU Rennes, Rennes, France

⁴ AHU Oral Surgery, CHU Rennes, Rennes, France

(Received: 10 February 2019, accepted: 3 June 2019)

Keywords:
tooth
autotransplantation
/ surgical protocol /
3D technology

Abstract – Introduction: This technical note presents the autotransplantation of an impacted third molar to replace a severely damaged homolateral molar using a surgical template of the tooth to be transplanted to prepare the recipient site based on an original protocol. **Technique:** Mandibular molar extraction is first performed, and autotransplantation is done after 7 days. Alveolar adjustment of the receiving socket is done using a resin replica of the tooth to be transplanted; the replica is obtained using DICOM diagnosis data. The three-dimensional (3D) replica is produced using 3D printing techniques with photopolymerizable methacrylate resin. Once the recipient site is ready, the transplant is avulsed. Immediate positioning of the tooth in the new socket will save a tremendous amount of extra-alveolar time. Cross-stitch sutures are done to obtain complete restraint, and endodontic treatment is administered after 15 days. Postoperative clinical and radiographic examination showed periodontal healing after postoperative 6 months. **Comments:** The use of the surgical template resulted in an extra-alveolar time of below 5 s and preservation of healthy periodontal ligament cells of the donor tooth as much as possible. **Conclusion:** The 3D technology, from imaging to printing, can drive the improvement of prognosis in a tooth autotransplantation protocol.

Introduction

Dental autotransplantation for the replacement of a tooth with an unfavorable prognosis, whether decayed or traumatized, was first described in the 1950s [1] and was then mainly optimized by Andreasen in the 1970s [2,3]. This technique involves the removal of a healthy tooth (which is most often non-functional) and its implantation at another site in the oral cavity of the same individual, either in an extraction cavity or a surgically prepared neo-alveolus [4].

It is necessary to individually assess the risk–benefit ratio of alternative solutions. Autotransplantation may have advantages over dental implants (which do not adapt to dentoalveolar development), fixed prostheses (which can damage the dental tissues of the adjacent teeth), and orthodontics (which can be time-consuming and lead to root resorption or gingival recession).

A grafted tooth benefits from the presence of the alveolar ligament that preserves proprioception, is resistant to occlusal load, and can adapt to its constantly changing environment.

To maintain the ligament's vitality, it is necessary to follow a precise surgical procedure. The maintenance of healthy periodontal ligament cells is one of the most important factors for therapeutic success and involves minimizing the extra-alveolar time required during the surgical phase [5]. Lee *et al.* were the first to propose the use of printed three-dimensional (3D) replicas based on radiological examination in their autotransplantation protocol [5]. Previously, a grafted tooth was first extracted and then tested several times at the new site until a good fit was achieved. This involved a relatively long extra-alveolar time, constraints on the alveolar ligament with a risk of cell damage, and, consequently, an increase in root resorption and ankylosis of the transplanted tooth [6].

Development of cone beam computed tomography (CBCT) has facilitated great precision in preoperative analysis and virtual surgical planning [7]. In addition to medical imaging, the use of 3D printing has developed in the field of medicine. In 1990, Palser *et al.* [8] reported on the possibility of producing models printed by stereolithography (STL) using tomographic image data. The principle of this technique is to retrieve the Digital Imaging and Communications in Medicine (DICOM)

* Correspondence: victor.fau@orange.fr

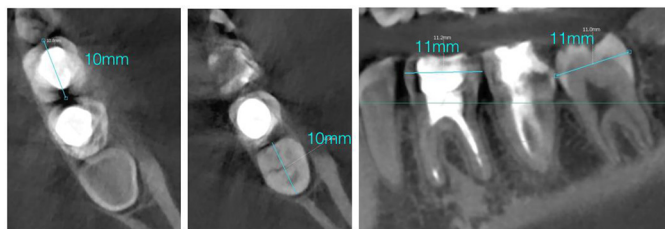


Fig. 1. Cone beam computed tomography sections and three-dimensional analysis of teeth 36 and 38.

data based on the CBCT results of the tooth to be replicated, convert the data into the STL format, and print the virtual structure with a 3D printer.

Using a clinical case study, this technical note highlights the growing interest in using a replica prepared using 3D printing technologies in autotransplantation.

Technique

A 20-year-old patient with no relevant medical or surgical history had localized pain affecting the left mandibular first molar. Although a few months ago, endodontic retreatment was performed, the retroalveolar image of the tooth showed a periapical lesion at the mesial root and the likely presence of an intra-channel broken instrument. The unfavorable long-term prognosis of this tooth indicated its extraction. After evaluating all alternative solutions, its replacement by transplantation of the enclosed left mandibular third molar was considered.

CBCT was performed to evaluate the shapes and dimensions of both teeth and the feasibility of the intervention. The mandibular third molar had two roots slightly shorter than those of tooth 36. Furthermore, the coronal mesiodistal widths of the two teeth were similar (Fig. 1). Therefore, the dental volumes allowed autotransplantation to be performed without prior orthodontic preparation.

To construct the surgical template of the tooth to be transplanted, digital data were exported in the DICOM format to the InVesalius[®] software. This software shows the plane-by-plane isolation of a tooth to be transplanted from the sections of the DICOM file (Fig. 2). Then, the digital data of the area of interest were exported as an STL file to the 3D modeling MeshMixer[®] software to smoothen the tooth surface. Finally, the STL file of this smoothed tooth was transferred to a 3D Formlabs[®] printer. A replica of the tooth was obtained by printing the template in photopolymerizable methacrylate resin (Fig. 3) and then sterilized in a steam autoclave with a 15-min cycle at 121 °C, as recommended by the resin supplier to avoid alteration of its dimensional stability.

The first step of the surgical procedure was the extraction of the mandibular first molar under local anesthesia and careful curettage of the periapical lesion (Fig. 4a and b).

After 7 days, the receiving site was prepared and adjusted with a round tungsten carbide bur mounted on a dental handpiece to adapt it to the printed replica. In particular, the inter-radicular bone septum had to be reduced. Once agreement between the

dental replica and receptor site was optimally achieved, the wisdom tooth was carefully extracted with forceps and immediately integrated into the neo-alveolus to minimize periodontal damage. The extra-alveolar time of the tooth was <5 s.

The transplanted tooth, slightly underoccluded, was fixed at the appropriate position by cross-stitch with a monocryl 3.0 suture (Fig. 5). Antibiotic therapy with 2 g amoxicillin per day was prescribed until the initial endodontic treatment of the tooth.

Endodontic treatment was performed 2 weeks after the transplantation, and the sutures were removed. A clamp, generally used to maintain the shape of teeth at transplant sites, was positioned on tooth 47 to avoid unnecessary trauma to the transplanted tooth. Soft tissues showed good healing, and the tooth was stable (mobility class 2 according to Mülheman).

After postoperative 6 months, clinical and radiological examinations revealed no functional impairment, resorption, or root ankylosis. Periodontal probing was done physiologically, and the tooth mobility was class 1 (Fig. 6).

Discussion

Dental autotransplantation is not often included in the therapeutic arsenal of tooth replacement because it is considered complex and operator dependent and has an unpredictable prognosis. However, the literature considers it a viable option for the replacement of a missing tooth, with estimated 1- and 5-year survival rates for autotransplantation of mature teeth reported to be 98.0 and 90.5%, respectively, according to a review of the recent literature [9].

Long-term results reported in a systematic review and Machado's meta-analysis showed a success rate ranging from 92% for immature teeth to 82% for those with complete root maturation [10]. In fact, complication rates after autogenous tooth transplantation are lower than those for dental implants [9,11].

The main complication of transplantation is root resorption, which occurs as soon as periodontal ligament cells are affected. Control of the extra-alveolar time is one of the main risk factors for affecting the vitality of periodontal ligament cells [2,12]. In 2001, Lee *et al.* proposed, for the first time, the use of computed tomography to produce a 3D surgical template model to reduce this time [5].

The surgical template identical to the tooth to be transplanted allows the optimal preparation of the recipient site, thus facilitating its immediate placement in the prepared cavity. Damage to periodontal ligament cells due to trials with the transplant to adjust a neo-alveolus is eliminated. This adjustment is optimally achieved with a surgical template. In fact, the use of the 3D model, in our clinical case, reduced the extra-alveolar time to below 5 s.

In our case, the two-stage surgical protocol was implemented because of the apical infection of tooth 36. Initially, the protocol involves careful curing of the alveolus after tooth extraction, followed by allowing natural healing for a few days before transplantation into a healthy scar tissue,

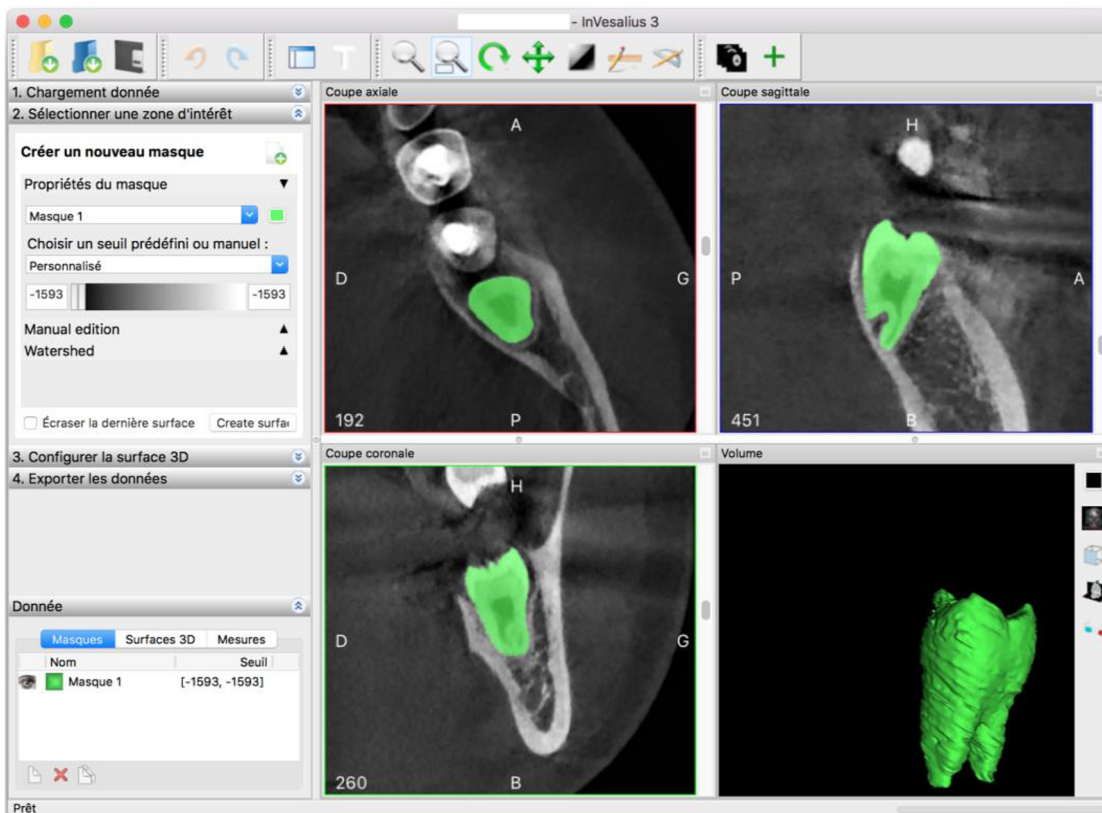


Fig. 2. Selection of the region of interest using the InVesalius® software.



Fig. 3. Methacrylate resin transplant surgical template.

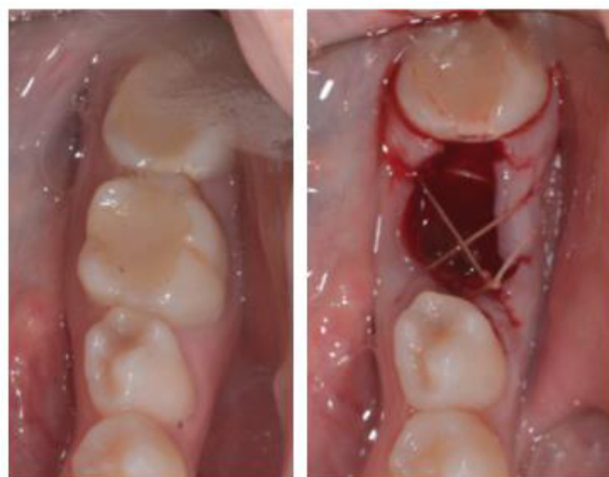

Fig. 4. Intraoral pictures before and after extraction of tooth 36.

which has not yet ossified and is rich in growth factors; this promotes the proper integration of the transplant and reduces the risk of ankylosis [13,14].

The quality and temporality of initial endodontic treatment (IET) are essential elements in the survival of transplants of apexified teeth. Many authors agree that this treatment should be performed 14 days after autotransplantation [9]. Exo-oral IET performed during surgery should be avoided because it increases the extraoral time and risk of periodontal cell and dentinal tubule contamination. On the contrary, an overly delayed IET, performed >14 days after autotransplantation, would lead to an increased risk of root resorption [9,15].

However, these statements have recently been challenged by a series of long-term case studies suggesting that under close supervision, some autotransplanted teeth with complete apical formation have the potential to undergo revascularization [16].

The use of autografts in this case has several advantages. It allowed the preservation of alveolar bone volume and maintenance of an attached gum around the graft. It was also the cheapest and most non-traumatic solution to replace

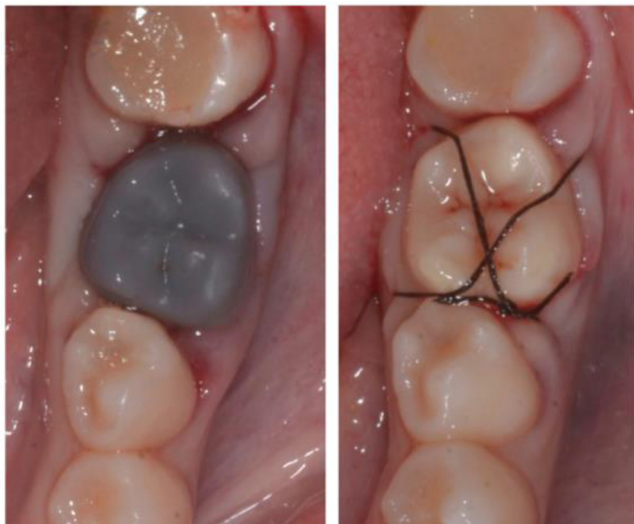

Fig. 5. Inspection of alveolar adaptation to the surgical template before transplantation, followed by the placement of the transplant.

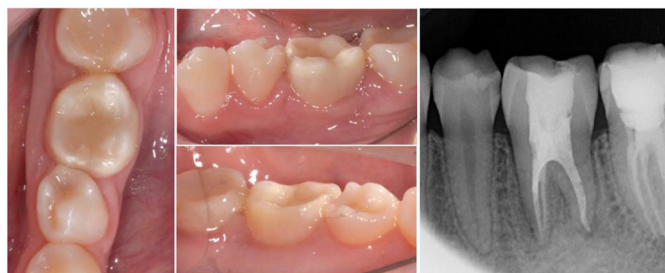

Fig. 6. Clinical and radiological situations 6 months after transplantation.

the missing tooth. In addition, by maintaining the periodontal ligament, possible orthodontic treatment can be considered in the long term if necessary.

Conclusion

Autotransplantation is an efficient treatment option for replacing a missing tooth. This solution is, contrary to popular belief, simple and has a good prognosis. It allows biological replacement of a missing tooth that evolves over time with the entire set of teeth, unlike implants. In addition, it has the advantage of being inexpensive. Access to digital computer-aided design/computer-aided manufacturing techniques and the development of CBCT indicates that the surgical template of the tooth to be transplanted is more easily accessible to surgeons. This template ensures that transplantation can be performed during the adaptation phase of the neo-alveolus, with the advantages described above, while significantly reducing the extra-alveolar time of the graft and thereby leading to a significantly better prognosis.

Conflicts of interests: The authors declare that they have no conflicts of interest in relation to this article.

References

1. Apfel H. Autoplasty of enucleated prefunctional third molars. *J Oral Surg* 1950;8:189–200.
2. Andreasen JO. Periodontal healing after replantation and autotransplantation of incisors in monkeys. *Int J Oral Surg* 1981;10:54–61.
3. Andreasen JO, Kristerson L. Evaluation of different types of autotransplanted connective tissues as potential periodontal ligament substitutes. An experimental replantation study in monkeys. *Int J Oral Surg* 1981;10:189–201.
4. Natiella JR, Armitage JE, Greene GW. The replantation and transplantation of teeth. A review. *Oral Surg Oral Med Oral Pathol* 1970;29:397–419.
5. Lee SJ, Jung IY, Lee CY, Choi SY, Kum KY. Clinical application of computer-aided rapid prototyping for tooth trans-plantation. *Dent Traumatol* 2001;17:114–119.
6. Hupp JG, Mesaros SV, Aukhil I, Trope M. Periodontal ligament vitality and histological healing of teeth stored for extended periods before transplantation. *Endod Dent Traumatol* 1998;14:79–83.
7. Anssari Moin D, Verweij JP, Waars H, Van Merkesteyn R, Wismeijer D. Accuracy of computer-assisted template-guided autotransplantation of teeth with custom three-dimensional designed/printed surgical tooling: a cadaveric study. *J Oral Maxillofac Surg* 2017;75:925.e1–925.e7.
8. Palser R, Jamieson R, Sutherland JB, Skibo L. Three-dimensional lithographic model building from volume data sets. *Can Assoc Radiol J* 1990;41:339–341.
9. Chung WC, Tu YK, Lin YH, Lu HK. Outcomes of autotransplanted teeth with complete root formation: a systematic review and meta-analysis. *J Clin Periodontol* 2014;41:412–423.
10. Machado LA, Do Nascimento RR, Ferreira DM, Mattos CT, Vilella OV. Long-term prognosis of tooth autotransplantation: a systematic review and meta-analysis. *Int J Oral Maxillofac Surg* 2016;45:610–617.
11. Almpani K, Papageorgiou SN, Papadopoulos MA. Autotransplantation of teeth in humans: a systematic review and meta-analysis. *Clin Oral Investig* 2015;19:1157–1179.
12. Hammarstrom L, Pierce A, Blomlof L, Feiglin B, Lindskog S. Tooth avulsion and replantation — a review. *Endod Dent Traumatol* 1986;2:1–8.
13. Nethander G, Anderson JE, Hirsch JM. Autogenous free tooth transplantation in man by a two stage operation technique. *Int J Oral Maxillofac Surg* 1988;7:330–336.
14. Marques-Ferreira M, Rabaca-Botelho MF, Carvalho L, Oliveiros B, Palmeirao-Carrilho EV. Histological evaluation of periodontal regeneration in autogenous tooth transplantation in the dog: a comparison between one and two-stage surgical techniques, a pilot study. *Dent Traumatol* 2010;26:76–79.
15. Jang Y, Choi YJ, Lee SJ, *et al.* Prognostic factors for clinical outcomes in autotransplantation of teeth with complete root formation: survival analysis for up to 12 years. *J Endod* 2016;42:198–205.
16. Murtadha L, Kwok J. Do autotransplanted teeth require elective root canal therapy? A long-term follow-up case series. *J Oral Maxillofac Surg* 2017;75:1817–1826.