Med Buccale Chir Buccale 2014;20:75-84
© SFCO, 2014
DOI: 10.1051/mbcb/2014010

www.mbcb-journal.org

MB Médecine Buccale Chirurgie Buccale CB

Original article

Study of the development of the area perilingularis

Rémi Curien, Cédric Baumann, Pierre Gangloff, Eric Gérard

Polyclinique de Gentilly - Médipôle St Jacques Maxéville, France

(Received 10 September 2013, accepted 30 March 2014)

Key words:
mandible / mylohyoid groove / ligaments / fascia / bone development / mandibular nerve

Abstract – Introduction: The *area perilingularis* is an anatomo-functional complex that gathers the mandibular foramen, the *lingula*, the *antilingula* and the mylohyoid groove. The development of these structures and their ontogenetic coordination have been poorly studied. **Material and methods:** Development scorings have been made and studied for each of these structures and their links. **Results and discussion:** These scorings have shown an ontogenetic evolution towards accentuation and migration of the reliefs. Moreover, the development of the structures was statistically linked. The determinism of the *area perilingularis,* inherited or under the influence of the environment, is discussed. The anthropological perspectives are numerous, and old anthropological conceptions concerning the *area perilingularis* are questioned.

Mots clés :
mandibule / sillon mylo-hyoïdien / ligament / fascia / développement osseux / morphogénèse / nerf mandibulaire

Résumé – Introduction : L'*area perilingularis* est un complexe anatomo-fonctionnel regroupant le foramen mandibulaire, la *lingula*, l'*antilingula* et le sillon mylo-hyoïdien. Le développement de ces structures et leur coordination ontogénétique sont encore peu connues. **Material and methods :** Des scores de développement ont été établis pour chaque structure puis leur comportement et corrélation ont été étudiés. **Results and discussion :** Ces scores ont montré une évolution ontogénétique sous la forme d'une accentuation et d'une migration des reliefs. De plus, le développement des structures était statistiquement lié. Le déterminisme de l'*area perilingularis*, hérité ou sous la dépendance de l'environnement, est discuté. Les perspectives anthropologiques sont nombreuses, et de vieilles conceptions concernant l'*area perilingularis* sont remises en question.

Introduction

According to Balogh and Csiba [1], the mandibular foramen (MF), the *lingula* and the mylohyoid groove form an anatomo-functional complex that they name *area perilingularis* (Fig. 1). The *lingula* and the edges of the mylohyoid groove have the same function of insertion of the sphenomandibular ligament (SML), which justifies their grouping within the same anatomo-functional entity. From this point of view, it would seem logical to add another structure of insertion of the sphenomandibular ligament [2, 3], the *antilingula*, not mentioned by Balogh and Csiba.

All these structures present subtle morphological variations, which have been extensively studied (for the *lingula*: 4-10; for the *antilingula*: 11-18; for the mylohyoid groove, especially studied for its covering structure, the mylohyoid bridge: 19-23). The study of the *area perilingularis* could offer numerous anthropological perspectives, such as:

- Indicative artefacts of a rank of development or of functional mandibular characteristics.
- Age determination according to the degree of development of its structures.
- Possible help for the determination of the sex.
- Determination of populations and even reconstruction of migrations and population links, like that proposed by Ossenberg [19] for the mylohyoid bridge.

However, most studies are primarily descriptive and the determinism of these structures, their development and biological significance have been poorly studied. Moreover, except in the case of Balogh and Csiba [1], these structures are still considered separately and not simultaneously in the *area perilingularis*.

* Correspondence: rcurien@gmail.com

Article publié par EDP Sciences

Fig. 1. Description of the structures of the *area perilingularis* (view from the inside of the left mandibular branch).
1: mandibular foramen; 2: *lingula*; 3: *antilingula*; 4: mylohyoid groove.
Fig. 1. Description des structures constitutives de l'area perilingularis (vue de la face interne de la branche mandibulaire gauche).
1 : foramen mandibulaire ; 2 : lingula ou épine de Spix; 3: antilingula ; 4 : sillon mylo-hyoïdien.

The first step towards better understanding of the *area perilingularis* would begin with better knowledge of its ontogeny, before further studies of its determinism or its interpopulational or sexual variations could be undertaken.

In the literature, it seems that the different aspects of these structures are considered as discrete discontinuous traits, isolated and morphologically fixed in a given individual.

Our hypothesis is that they are rather different stages in the continuous development trend, common to the whole *area perilingularis*.

This article thus aims to describe the development of the structures of the *area perilingularis* (integrating the *antilingula*) during post-natal ontogeny, and studying their correlations in terms of development.

Materials and methods

Two hundred and fourteen mandibles were studied. They were consulted in several osteological collections (Museum of Man, Paris; Laboratory of Anthropology of the Faculty of Medicine of Marseille, UMR 6578; Institute of Normal Anatomy of the Faculty of Medicine of Strasbourg).

They are classified in 4 groups of dental age bounded by the eruption of the permanent molars, which are very meaningful benchmarks for studies of development [25]. The distribution is detailed in Table I.

Table I. Distribution of the morphology and development scores of the lingular blade as a function of age. The results are expressed as percentages.
Tableau I. Distribution des scores de morphologie et de développement de la lame lingulaire en fonction des classes d'âge. Les résultats sont exprimés en pourcentages.

		Morphology			Development		
		1	2	3	1	2	3
		Number					
	Total						
M1	166	87	64	15	15	64	87
M2	77	40	28	9	3	18	56
M3	80	44	26	10	0	11	69
Adults	105	53	24	28	0	17	88
	428						
		Percentages					
M1		52.41	38.55	9.04	9.04	38.55	52.41
M2		51.95	36.36	11.69	3.9	23.38	72.73
M3		55	32.5	12.5	0	13.75	86.25
Adults		50.48	22.86	26.67	0	16.19	83.81

M1: period comprised between birth and éruption of the first molar.
M2: period comprised between éruption of the first molar (excluded) and eruption of the second molar (included).
M3: period comprised between éruption of the second molar (excluded) and eruption of the third molar (included).
Scores 1, 2, 3 for morphology and development correspond to a gradation of what seems (after preliminary study of the mandibles) to appear progressively during the development of the structures.

A preliminary observation of all the osteological materials (two independent observers) allowed us to elaborate a progressive morphological classification of the structures by a developmental gradation of the identified morphological types, with a system of scores (0, 1, 2, 3). Scores thus correspond to a gradation of what seems (after preliminary observation) to appear progressively during the development of the structures.

The correspondence of these classifications with reality was verified by a comprehensive survey of their capacity to describe all the morphologies met in the materials (two independent observers).

Fig. 2. Basic form of *area perilingularis*.
Fig. 2. Forme élémentaire de l'area perilingualis.

A study of development was performed by means of a Chi-squared test of comparison of age groups, and of a descriptive analysis of the distribution of the classifications according to age groups, to observe their ontogenetic evolution.

The distributions of frequencies within each classification in the adult class were analyzed.

Finally, a study of the possible relations between the various structures codified by classifications was carried out by means of a Chi-squared test of independence.

Results

Our observations highlight a basic structure that is present in the early stages (Fig. 2): the mandibular foramen (MF) itself. It forms a clearly circular opening facing upward and backward, and in the early stages of development is free of appendices and coverings.

It is observed that in many cases, in the immature (Fig. 3), the anterior edge of the MF seems to be doubled and have two lips. A posterior lip corresponds to the anterior border (as such) of the MF, and an anterior lip covers the previous component and constitutes the posterior border of a tongue-like relief extending the mandibular body, and whose lower edge is the mylohyoid groove. When the lingular blade protrudes behind the anterior border of the MF, it forms the *lingula*.

The lingular blade can be classified according to the degree of posterior development:

- Score 1: posterior edge of the lingular blade before the anterior border of the MF, with an apparent duplication of this border.

Fig. 3. The two lips of the anterior border of the FM. The two arrows indicate the two lips.
Fig. 3. Dédoublement du bord antérieur du FM. Les deux flèches indiquent les deux lèvres du bord antérieur.

- Score 2: lingular blade confused with the anterior edge of the MF, no double lip-border.
- Score 3: posterior border of the lingular blade posterior to the anterior margin of the MF. Presence of a *lingula*.

The posterior border of the lingular blade appears to present several morphologies, which can be grouped in three scores:

- Score 1 (Fig. 4): predominance of a superior spine or a superior tubercle. An inferior spine may be present but the superior spine predominates.
- Score 2 (Fig. 5): no predominance of a superior or an inferior spine. This class includes rounded spatulas, flattened spatulas or double spines.
- Score 3 (Fig. 1): prevalence of an inferior spine (the superior spine forming a simple lingular tubercle) giving the appearance of the conventional triangular *lingula*.

The morphology and even the presence of the *antilingula* (Fig. 6) is often uncertain; although it sometimes takes a prominent triangular shape, it is often difficult to distinguish from an insertion ridge of the medial pterygoid muscle or from the posterior extension of the lower edge of the mylohyoid groove. The forms of *antilingulae* can be grouped into three categories:

- Score 0: no *antilingula*.
- Score 1: ridge.
- Score 2: triangle with a broad base.

The mylohyoid groove presents different degrees of development (Fig. 7):

- Score 0: no groove.
- Score 1: concavity without sharp edges.
- Score 2: groove with sharp edges.

The mylohyoid bridge also presents different stages of development (Fig. 8) that are in agreement with the observations of Kaul and Pathak [22]:

- Score 0: no bridge.
- Score 1: thin "sawtooth" lamellas on the edges of the groove.

Fig. 4. Three aspects of the *lingula* with predominant superior spine.
A: lingular tubercle (1); B: superior spine (2); C: no predominance of a superior or an inferior spine (3).
Fig. 4. Trois aspects de la lingula à pointe supérieure prédominante.
A : tubercule lingulaire (1) ; B : épine supérieure (2) ; C : épine inférieure ne prédominant pas sur l'épine supérieure (3).

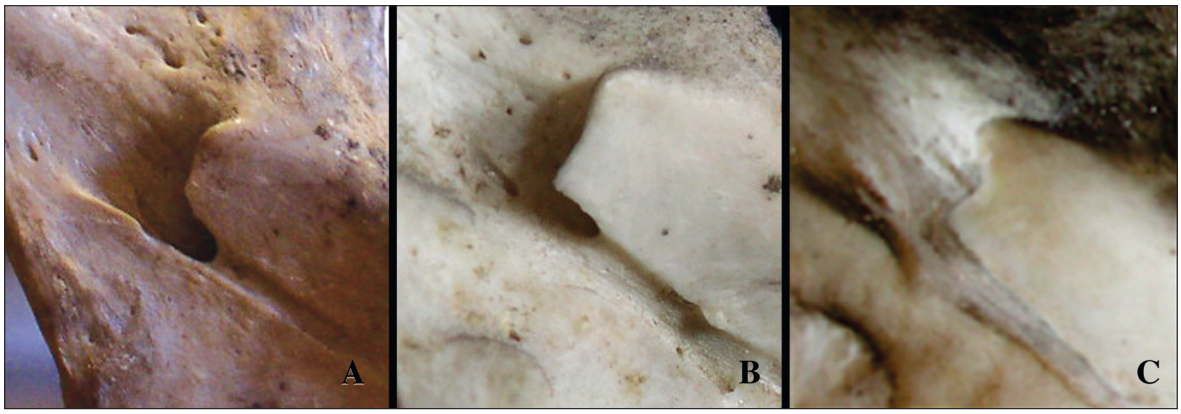

Fig. 5. Three aspects of the spatula-shaped *lingula*.
A: rounded spatula; B: flattened spatula; C: double spine.
Fig. 5. Trois aspects de la lingula à forme en spatule.
A : spatule arrondie ; B : spatule aplatie ; C : double pointe.

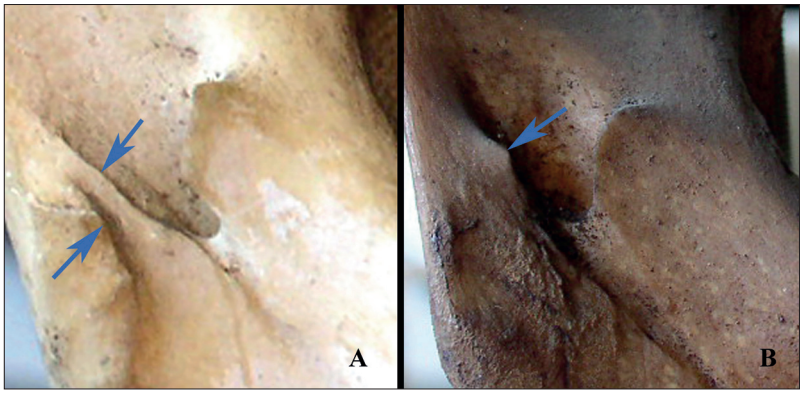

Fig. 6. Two aspects of the *antilingula*.
A: ridge (upper arrow), to distinct from an insertion ridge of the internal pterygoid muscle (lower arrow); B: triangle with broad based.
Fig. 6. Deux aspects de l'antilingula.
A : crête (flèche supérieure), à distinguer d'une crête d'insertion du ptérygoïdien interne ; B : triangle à base large.

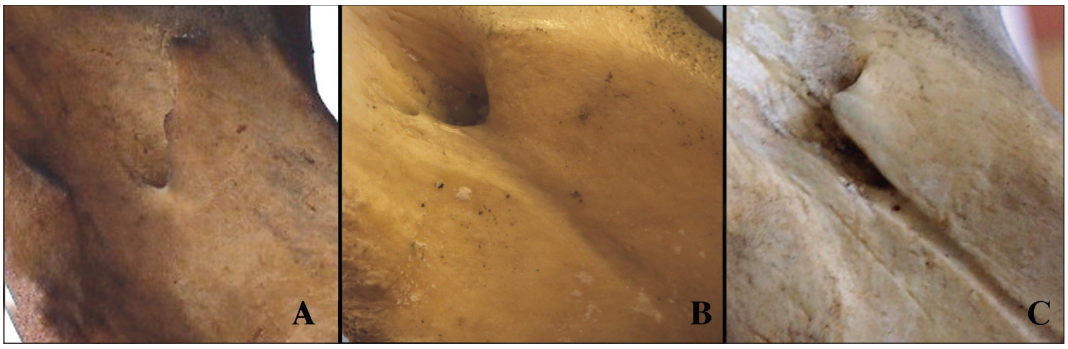

Fig. 7. Aspects of the mylohyoid groove.
A: no; B: concavity without sharp edges; C: groove with sharp edges. Note the presence of an inferior spine to the *lingula*.
Fig.7. Aspects du sillon mylo-hyoïdien.
A : absence ; B : relief négatif ; C : gouttière aplatie ; noter la présence d'une lingula à pointe inférieure.

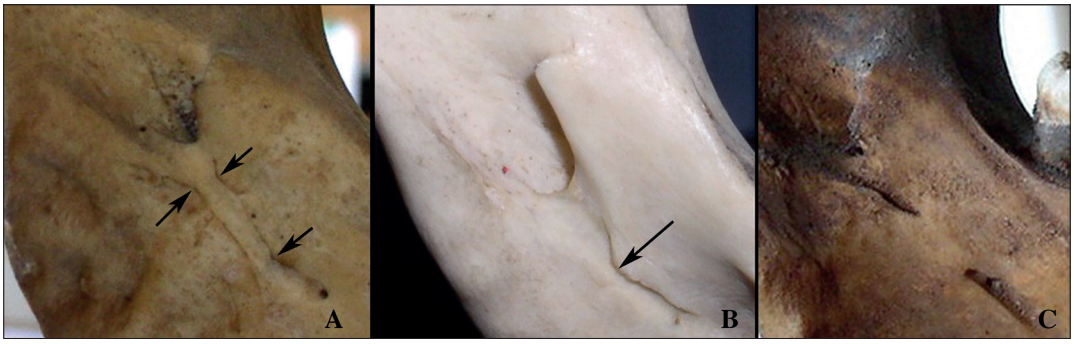

Fig. 8. Aspects of the mylohyoid bridge.
A: lamellas; B: incomplete bridge; C: complete bridge.
Fig. 8. Aspects de l'arche mylo-hyoïdienne.
A : lamelle ; B : arche incomplète ; C : arche complète.

- Score 2: incomplete tunnel by development of the lamellas towards each other or by a plaque almost joining the opposite edge.
- Score 3: complete tunnel.

Such lamellas are sometimes visible on *antilingula* or *lingula* and could be an extension of a lamella covering the mylohyoid groove, thus being a single entity covering the mylohyoid groove and MF.

In some cases, the *lingula* and the area of the *antilingula* are completely connected by a bone lamella (Fig. 9); in this case, the *lingula* and the *antilingula* are not classified.

The results of the study on development of the *area perilingularis* using the classification system developed above are presented in Tables I, II and III and the corresponding diagrams (Fig. 10). These classifications have enabled us to classify all the cases encountered in our sample.

The Chi-squared tests were performed after calculation of a Kappa coefficient of concordance of the sides (left / right) for each variable: the latter showing a moderate to good concordance of each variable (Tab. IV), the Chi-squared tests were conducted on only one side (left).

The Chi-squared test comparing age groups for each variable shows a significant influence of age on the distribution of classes ($p < 0.05$ for all 5 variables).

The results of the Chi-squared test of independence (comparing variables to each other) are presented in Table V.

Discussion

The classifications developed have enabled us to classify every case in our sample. They could therefore be considered as a good representation of reality. However, a study of repeatability and reproducibility is required before any definitive conclusions can be drawn.

Fig. 9. Horizontal-oval shape of the mandibular foramen (HOFM).
Fig. 9. Forme horizontale-ovale du foramen mandibulaire (HOFM).

Table II. Distribution of the morphology and development scores of the *antilingula* as a function of age. The results are expressed as percentages.
Tableau II. Distribution des scores de développement de l'antilingula en fonction des classes d'âge. Les résultats sont exprimés en pourcentages.

		0	1	2
		Number		
	Total			
1-6 years	166	64	101	1
6-13 years	77	24	45	8
13-21 years	80	27	48	5
Adults	105	38	52	15
	428			
		Percentages		
1-6 years		38.55	60.84	0.60
6-13 years		31.17	58.44	10.39
13-21 years		33.75	60	6.25
Adults		36.19	49.52	14.28

From a general point of view, the relief of the *area perilingularis* tends to accentuate during ontogeny: marked development scores increase in frequency at the expense of low development scores. Our classification systems are therefore a good representation of development.

Table III. Distribution of the morphology and development scores of the mylo-hyoid groove and the mylo-hyoid bridge as a function of age. The results are expressed as percentages.
Tableau III. Distribution des scores de développement du sillon mylo-hyoïdien et de l'AHM (arche mylo-hyoïdienne) en fonction des classes d'âge. Les résultats sont exprimés en pourcentages.

		Development			Mylohyoid groove			
		0	1	2	0	1	2	3
		Number						
	Total							
1-6 years	166	9	113	44	163	3	0	0
6-13 years	77	0	28	49	65	11	0	1
13-21 years	80	0	25	55	35	42	2	1
Adults	105	0	14	91	34	54	12	5
	428							
		Percentages						
1-6 years		5.42	68.07	26.51	98.19	1.81	0	0
6-13 years		0	36.36	63.64	84.41	14.28	0	1.3
13-21 years		0	31.25	68.75	43.75	52.5	8	1.25
Adults		0	13.33	86.67	32.38	51.43	85.71	4.76

Development of the *lingula*

Our observations suggest that the *lingula* is the posterior border of a larger structure, emerging from the back of the body of the mandible: the lingular blade. This view is consistent with embryological data: during embryogenesis, the main mandibular core (mandibular body) emits a spatuliform apophysis whose lower limit corresponds to the mylohyoid groove and whose posterior border foreshadows the *lingula* [26, 27].

Our study of ontogenesis shows that there is, in a certain proportion of cases, a "descent" and to a lesser extent posterior development of the tip of the lingular blade during ontogeny. The proportion of lingular blades with predominant inferior spine remains relatively stable.

The *lingula* would therefore present some changes during ontogeny and its morphology is not fixed at birth. This observation makes Gaspard's hypothesis plausible [2], in which the formation of the *lingula* (and *antilingula*) may result, as the mylohyoid bridge, from a postnatal ossification of the fibrous opercule inserting on it. The uninterrupted depression between the *lingula* and *antilingula*, and between the edges of the mylohyoid groove, is capped by the interpterygoid aponeurotic system. This system gathers in a single ensemble the interpterygoid fascia, the sphenomandibular ligament and the vascular

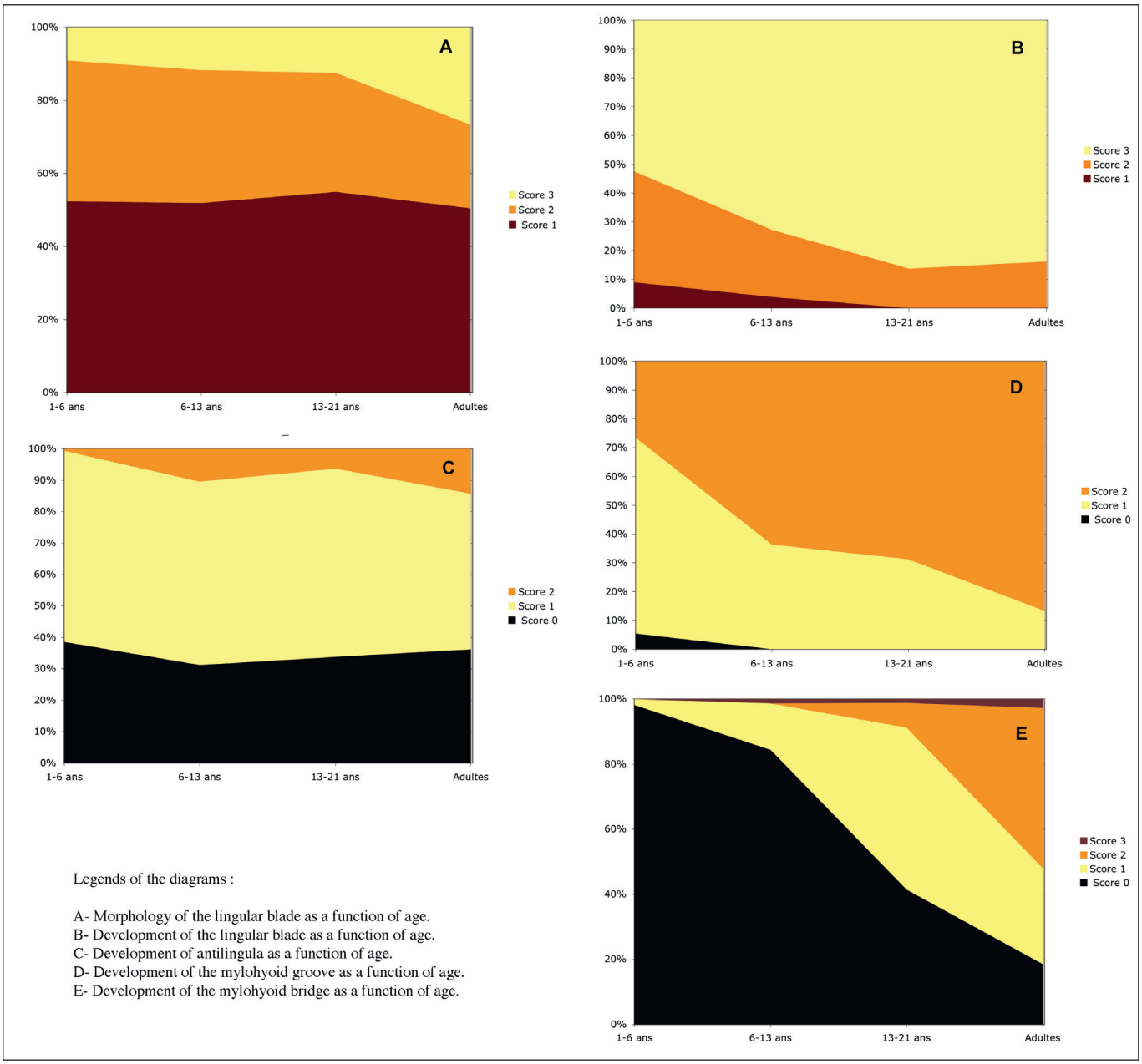

Fig. 10. Diagrams of development of the structures of the *area perilingularis*.
Fig. 10. Schéma du développement des structures de l'area perilingularis.

blade of Hovelacque and Virenque [28], fascia inserting between the two beams of the sphenomandibular ligament. However, we must note that according to Garg and Townsend [29], the morphology of the *lingula* does not seem to correlate with the size of ligament insertions.

Finally, the lingular types described by our classification system, as well as their distribution in adults, are consistent with other articles on the subject [4, 6, 7, 10].

Development of the *antilingula*

In most cases (85.72% in adults), the *antilingula* is absent or represented by a ridge and thereby indistinguishable from the upper border of the angular apophysis, a posterior extension of the mylohyoid groove and/or the pterygoid ridge, inferior insertion of the interpterygoid aponeurosis [30]. This uncertain status has already been mentioned in the

Table IV. Calculation of the Kappa coefficient of concordance of the sides, and its interpretation.
Tableau IV. Calcul du coefficient de Kappa selon le côté, et son interprétation.

Variable	Kappa coefficient	Concordance
Lingular blade, morphology	0.58	Moderate
Lingular blade, development	0.71	Good
Antilingula	0.49	Moderate
Mylohyoid groove, development	0.64	Good
Mylohyoid bridge	0.58	Moderate

Table V. Results of Chi-squared test of independence (*p* values). Non-statistically significant associations are highlighted in yellow.
LBM: lingular blade, morphology. LLD: lingular blade, development. AL: *antilingula*. MHG: mylohyoid groove. MHB: mylohyoid bridge.
Tableau V. Résultats du test du Khi 2 d'indépendance (valeurs de p).
LLM : lame lingulaire, morphologie. LLD : lame lingulaire, développement. AL : antilingula. SMH : sillon mylo-hyoïdien. AMH : arche mylo-hyoïdienne.

	LBM	LBD	AL	MHG	MHB
LBM		<0.0001	0.015	0.08	0.0054
LBD	<0.0001		0.0548	<0.0001	0.003
AL	0.015	0.0548		0.002	<0.0001
MHG	0.08	<0.0001	0.002		<0.0001
MHB	0.0054	0.003	<0.0001	<0.0001	

literature [11, 14, 15, 18]. It is perhaps for this reason that Balogh and Csiba [1] do not mention it in their description of the *area perilingularis*. It would actually be observable, with its characteristic triangular broad-based form, in a minority of cases (not before 6 years, 14.28% of adults). These facts must be put in perspective with the anatomy of the sphenomandibular ligament. According to Shiozaki et al. [31], if it always inserts on the *lingula* by its anterior extension, its posterior extension (which is supposed to insert on the *antilingula*) is poorly systematized: it is absent in 12.5% of cases, extends toward the posterior border of the mandible in 57.5% of cases, and is inserted behind the foramen in 30% of cases. It is possible to observe an *antilingula* only in the latter case, and in other cases there would probably be no relief or a single peak.

Development of the mylohyoid groove

We observe a deepening and a strengthening of the mylohyoid groove during development and in some cases the gradual appearance of a mylohyoid bridge. This last aspect may vary, as specified by Kaul and Pathak [22], from a simple outline to a full deck. It could be that this structure results from progressive ossification of the blade of Hovelacque and Virenque [28]. Depending on the individual, the process would stop at a more or less advanced stage (genetically programed or in connection with the function).

Our classification of the mylohyoid bridge does not follow the classic dichotomous (presence / absence) distinction used in the majority of publications on the subject [19-23]. A classification using intermediate stages of development, as in the present study, would possibly consider interpopulation and age variations with more precision.

Therefore, if we recognize the drafted and incomplete forms of this structure, it is far more common than the literature implies: its incidence is 67.6% in adults in the present study, while it is always below 33.8 % and very often below 10% in the other articles [19-23]. This observation could challenge the view that the mylohyoid bridge is a genetic trait [22] and its use (in its dichotomous classification) as an anthropological tool. It may not be a single phenotype, but the extreme development of a very common and very variable structure.

According to Ossenberg [22], the mylohyoid bridge appears to be a genetically determined variant of Meckel's cartilage, whose remnants remain an osteogenic potential reactivated at the pubertal growth spurt. This last point is discordant with our own observations of complete and incomplete mylohyoid bridges before the age of puberty.

Coordinated nature of the area *perilingularis*

Ontogenetically, the 3 structures that form the *area perilingularis* (*lingula*, *antilingula*, mylohyoid groove and its annexes) have coordinated development between them, which

could result from the same process of ossification of the fascial blades inserting on the edges of the groove. The Chi-squared test also shows a statistically significant relationship between the variables studied, except in regard to comparison of development of the *antilingula* and that of the lingular blade on the one hand, and to comparison of development of the mylohyoid groove and morphology of the lingular blade, on the other. In the first case, the lack of a link could simply result from the uncertain nature and even uncertain presence of the *antilingula*, as explained above. In the second case, an explanatory hypothesis may lie in the fact that the morphology of the lingular blade does not depend only on the degree of calcification of the interpterygoid fascial system (as would however be the case for the development of the mylohyoid groove), but also on the vector forces exerting on it (see below).

Anatomically, it is possible to reduce the *area perilingularis* to a single structure forming a groove oriented from bottom to top and from front to back, completed by an open funnel in its posterior part (wherein the MF). The essential structures of the *area perilingularis*, those determining its morphology and its function, are the edges of the groove. These edges belong:

- For the upper edge, to the mandibular body (or *basal unit*) in its posterior extension, the lingular blade, persistence of the spatuliform apophysis. These two components fall within the same structure. The continuity between the *lingula* and the superior border of the mylohyoid groove has already been mentioned by Fabian [8] and Garg and Townsend [29].
- For the lower edge, to the *angular unit*. This lower edge is formed of the pterygoid ridge or the *antilingula*, and of the lower edge of the mylohyoid groove.

The groove is thus a clear boundary between two different anatomo-functional structures from the subdivision established by Moss [32]: the *basal unit* and the *angular unit*.

From a functional point of view, the edges of the groove bringing together all the structures of the *area perilingularis* contribute to a single function: the insertion of the interpterygoid fascial system. This system, inserting both on the skull base and on the mandible, takes part in mandibular movements. The sphenomandibular ligament, particularly, restricts movements of the mandible, helps maintain temporomandibular joint stability [33], and its lower attachment to the *lingula* is at the axis of rotation of the mandible [6]. Thus, a heavier load or displacement of the solicitations epicenter (center of rotation of the mandible?) could enhance the development of the whole *area perilingularis*. The backward development of the lingular blade during growth may result from the forward growth of the mandible while the center of rotation of the mandible does not follow this movement. Moreover, according to Smith [25], the more the space between the *lingula* and *antilingula* is "filled", the more the distance between the cranial and the mandibular insertions of the SML is reduced, which also reduces the stress exerted on the SML by a reduction of the lever arm. However, we must recall that according to Tuli et al. [6], the sphenomandibular ligament sustains no lengthening or tension in all movements of the jaw.

A detailed study of mandibular mechanics in this region, correlated with the morphology of the *area perilingularis*, could be rich in information. In an extreme of this tendency, the *lingula* and the area of the *antilingula* are completely connected by a bone lamella, forming what Smith [25] called the horizontal-oval form of the mandibular foramen (HOMF).

These considerations could explain the sexual dimorphism observed for the *lingula* by Tuli et al. [6], according to which robust (nodular) *lingulae* are more common in men than in women. The forces exerted on the *lingula* by the SML could be stronger in men. But it is also possible that the shape of the *lingula* is at least partly under the influence of endocrine factors.

At this stage of our studies, the determinism of the structures of the *area perilingularis* still remains unclear: are they inherited traits of endogenous determinism, are they adaptive structures under the influence of the environment through the sphenomandibular ligament, or both? This issue needs to be studied and is currently under investigation.

Conclusion

The *area perilingularis* is a homogeneous anatomo-functional and developmental ensemble where the distinction of isolated structures would be of descriptive interest but does not correspond to reality. The development of its structures is progressive and coordinated. Some aspects previously considered as discrete phenotypic traits do in fact correspond to grades of this progressive development, which is variable depending on the individual and possibly on the population. Finally, the structures of the *area perilingularis* present very subtle variations, which could contain multiple anthropological clues as to the identity of the holder, such as population, lifestyle, and age.

Conflicts of interests: none declared

References

1. Balogh K, Csiba A. Anatomo-topographic variations of the *lingula* and the opening of the mandibular canal (*area perilingularis*). *Bull Group Int Rech Sci Stomatol* 1966;9:145-56.
2. Gaspard M. L'appareil manducateur et la manducation. Tome 1, Anatomie descriptive, ontogénèse et phylogénèse de la mandibule humaine. Paris : J. Prélat, 1978.
3. Rouviere H, Delmas A. Anatomie humaine descriptive, topographique et fonctionnelle. Tome 1: tête et cou. 15th ed. Paris: Masson, 2002.

4. Depreux R. Variations topographiques et morphologiques de l'épine de Spix chez l'adulte. *Arch Anat Path* 1958;6:92-5.
5. Libersa JC, Libersa C, Laude M, Thilloy G. The Spix spine: anatomic study of a homogeneous population (50 cases). *Arch Anat Pathol* 1975;23:295-7.
6. Tuli A, Choudhry R, Choudhry S, Raheja S, Agarwal S. Variation in shape of the *lingula* in the human adult mandible. *J Anat* 2000; 197:313-7.
7. Devi R, Arna N, Manjunath KY, Balasubramanyam M. Incidence of morphological variants of mandibular *lingula*. *Indian J Dent Res* 2003;14:210-3.
8. Fabian FM. Observation of the position of the *lingula* in relation to the mandibular foramen and the mylohyoid groove. *Ital J Anat Embryol* 2006;111:151-8.
9. Jansisyanont P, Apinhasmit W, Chompoopong S. Shape, height, and location of the *antilingula* for sagittal ramus osteotomy in Thais. *Clin Anat* 2009;22:787-93.
10. Murlimanju BV, Prabhu LV, Pai MM, Paul MT, Saralaya VV, Kumar CG. Morphological study of *lingula* of the mandibles in south indian population. *Morphologie* 2012;96:16-20.
11. Yates C, Olson D, Guralnick W. The *antilingula* as an anatomic landmark in oral surgery. *Oral Surg Oral Med Oral Pathol* 1976; 41:705-8.
12. Langston JR, Tebo HG. The incidence and relationship of the lateral ramus prominence to the mandibular foramen. *Oral Surg Oral Med Oral Pathol* 1977;44:190-6.
13. Martone CH, Ben Joseph AM, Wolf SM, Mintz SM. Dimorphic study of surgical anatomic landmarks of the lateral ramus of the mandible. *Oral Surg. Oral Med Oral Pathol* 1993;75:436-438.
14. Pogrel MA, Schmidt BL, Ammar A. The presence of the *antilingula* and its relationship to the true *lingula*. *Br J Oral Maxillofac Surg* 1995;33:235-238.
15. Hogan G, Ellis E 3rd. The "*antilingula*"- fact or fiction? *J Oral Maxillofac Surg* 2006;64:1248-54.
16. Aziz SR, Dorfman BJ, Ziccardi VB, Janal M. Accuracy of using the *antilingula* as a sole determinant of vertical ramus osteotomy position. *J Oral Maxillofac Surg* 2007;65:859-62.
17. Apinhasmit W, Chompoopong S, Jansisyanont P, Supachutikul K, Rattanathamsakul N, Ruangves S, Sangvichien S. The study of position of *antilingula*, midwaist of mandibular ramus and midpoint between coronoid process and gonion in relation to *lingula* of 92 Thai dried mandibles as potential surgical landmarks for vertical ramus osteotomy. *Surg Radiol Anat* 2011; 33:337-43.
18. Monazzi MS, Passeri LA, Gabrielli MF, Bolini PD, De Cravalho WR, Da Costa Machado H. Anatomic study of the mandibular foramen, *lingula* and *antilingula* in dry mandibles, and its statistical relationship between the true *lingula* and the *antilingula*. *Int J Oral Maxillofac Surg* 2012;41:74-78.
19. Ossenberg NS. The mylohyoid bridge: an anomalous derivative of Meckel's cartilage. *J Dent Res* 1974;53:77-82.
20. Sawyer DR, Allison MJ, Elzay RP, Pezzia A. The mylohyoid bridge of pre-columbian peruvians. *Am J Phys Anthropol* 1978;48:9-15.
21. Lundy JK. The mylohyoid bridge in the Khoisan of Southern Africa and its unsuitability as a mongoloid genetic marker. *Am J Phys Anthropol* 1980;53:43-8.
22. Kaul SS, Pathak RK. The mylohyoid bridge in four population samples from India, with observations on its suitability as a genetic marker. *Am J Phys Anthropol* 1984;65:213-8.
23. Manjunath KY. Mylohyoid bridging in South Indian mandibles. *Indian J Dent Res* 2003;14:206-9.
24. Smith BH, Crummett TL, Brandt KL. Ages of eruption of primate teeth: a compendium for aging individuals and compare life histories. *Yearbook of Physical Anthropology*, 1994;37:177-231.
25. Smith FH. Evolutionary signifiance of the mandibular foramen area in Neanderthals. *Am J Phys Anthropol* 1978; 48: 523-32.
26. Wissmer A. Le développement et l'organisation statique de la mandibule fœtale chez l'homme. *Arch Anat Histol Embryol* 1927;7:335-426.
27. Bollobas E. Embryonic development of the mandibular canal. *Acta Morphologica Acad Sci Hung* 1982;30:233-239.
28. Hovelacque A, Virenque M. Les formations aponévrotiques de la région ptérygo-maxillaire chez l'homme et chez quelques mammifères. *Anat Phys* 1913;49:427-88 et 618-699.
29. Garg A, Townsend G. Anatomical variation of the sphenomandibular ligament. *Aust Endod J* 2001;27:22-4.
30. Laison F, Gaudy JF. Anatomie cranio-faciale. Paris : Masson, 1993.
31. Shiozaki H, Abe S, Tsumori N, Shiozaki K, Ichinohe T. Macroscopic anatomy of the sphenomandibular ligament related to the inferior alveolar nerve block. *Cranio* 2007;25:160-5.
32. Moss ML. Functionnal cranial analysis of mammalian mandibular ramal morphology. *Acta Anat* 1968;71:423-47.
33. Paschetta C, De Azevedo S, Castillo L, Martinez-Abadias N, Hernandez M, Lieberman DE, Gonzalez-Jose R. The Influence of Masticatory Loading on Craniofacial Morphology: A Test Case Across Technological Transitions in the Ohio Valley. *Am J Phys Anthropol* 2010;141:297-314.